

The history of familial adenomatous polyposis

Steffen Bülow¹, Terri Berk² and Kay Neale³

¹*The Danish Polyposis Register, Hvidovre University Hospital, Copenhagen, Denmark;* ²*The Familial Gastrointestinal Cancer Registry, University of Toronto, Canada;* ³*The Polyposis Registry, St. Mark's Hospital, Northwick Park, Watford, Harrow, UK*

Introduction

The first convincing case of familial adenomatous polyposis was published 120 years ago, and in the first half of this period the disease was primarily described and managed by surgeons and pathologists. Since the discovery of the *APC* gene, familial adenomatous polyposis has changed into a disease, which is nowadays diagnosed, treated and controlled by a multidisciplinary team of specialists. This is undoubtedly the main cause of the exponential development of research into all aspects of the disease, which has taken place during the last two decades and has resulted in substantial improvements in treatment, survival and quality of life.

The aim of this article is to present a chronological review of the history of the disease.

Polypoid disease

The first known description of multiple colorectal polypoid lesions dates from 1721 and was published in Latin by Menzel in a medical journal from Berlin, Germany. He drew an 18-cm colonic segment with 15 wart-like mucosal and submucosal excrescences at a post mortem of a 15-year-old boy who died of dysentery [1]. The theme of polypoid projections was picked up again in 1832, when Wagner reported 20 tiny polyps as the sequelae of healed ulcers [2]. Rokitsky described the new thickened tissue forming the fibrous base from which rose projections, some of them small, some big, giving the originally rounded edges of the mucous lacunae a fringed, serrated appearance [3]. In 1847, Corvisart detailed hypertrophied features from the anatomy specimen of a 22-year-old male with more than 20 excrescences in the ascending colon. Interestingly, a colleague wondered about the malignant potential, only to be told by the author that no trace of cancerous change was to be found [4].

In that era, the purported sequence of events leading to polyps began with rectal haemorrhage, followed by mucosal prolapse, chronic inflammation, diarrhoea/dysentery, scarring, and follicular hypertrophy of the

rectal mucosa (in fact this last was part of the ulcerative process). Lebert in 1857 described a 32-year-old female with a history of dysentery; autopsy showed hundreds of colorectal polyps with inflammation [5]. In 1859, a thesis on rectal polyps by Chargelaigue noted 2 living cases, both successfully treated with surgery, including a 16-year-old girl operated on by Robert for over 27 polyps and a 21-year-old male who had 80–100 polyps excised by Richet. In both cases, an early history of rectal bleeding or chronic diarrhoea was observed [6]. Autopsy case reports by Lebert and Luschka of diarrhoea-prone women in their early thirties with hundreds to thousands of polyps would come to be classified by the pathologist Virchow with a specific disease, colitis polyposa, and included Menzel's case [5, 7]. In 1863, Virchow found microscopic evidence of dilated crypts of Lieberkühn filled with mucous and the formation of retention cysts, which were later ascribed to the end stage of ulcerative colitis [8]. By 1881, Woodward classified pseudo-polyps in the submucosa of a 44-year-old female as the result of long-term inflammation, quite apart from colitis polyposa, where the mucosa between the polyps was normal. In fact, Woodward questioned whether Menzel's description did not better match that of pseudo-polyps and, though rare, was unrelated to carcinoma [9]. These early descriptions of "polyposis" are replete with misperceptions and misnomers but, clearly, histopathology remains the driving force in its evolution. Prior to the 1860s autopsy findings informed the literature but were observational in nature and linked to intestinal inflammation.

Adenomatous polyposis

Sklifasowski published the first histologically verified case of adenomatous polyposis in Russia in 1881 (Figure 1). He described a 51-year-old merchant with a history of 7 years of bloody diarrhoea and abdominal pain. Rectal examination revealed multiple excrescences, and at operation with incision above the inguinal ligament and colotomy large polyps were removed. Histological examination showed multiple adenomas

[10]. In 1882, attention would also turn toward the inherited predisposition for what Cripps termed “disseminated polypos of the rectum” on the basis of 20–30 adenomas in two affected siblings, aged 17 and 19, both of whom experienced rectal haemorrhage from prepuberty. The extreme rarity of multiple polypi, unlike the singular polyp, was emphasised [11]. Whitehead in 1884 presented a 21-year-old woman with a huge prolapsing rectal adenoma, which was resected. The patient became continent, despite the fact that the surgeon had “his arm beyond the elbow passed up the bowel” [12].

In 1887, Smith reported three affected siblings with microscopic features of soft, vascular, gland polyps called adenoid, one of which died of cancer at age 26 years. Although three affected siblings were remarked upon, no mention is made of an affected parent [13]. In 1890, Bickersteth [14] would also document an affected mother and her 11-year-old son along with the importance of this genetic connection. Bussey, however, found this case and that of Bickersteth more in keeping with juvenile polyposis [15], and, in general, the early diagnosis of adenoma may include cases of juvenile polyps as well as Peutz–Jeghers polyps. In 1890, Cripps [16] would go on to distinguish pedunculated disseminated adenoid polypi from the villous tumour with its premalignant potential. The same year Handford would confirm the association with cancer in his autopsy report of a 34-year-old woman, noting the absence of a family history of disease, setting the stage for more accurate histological investigation [17]. Dalton [18] in 1893 described a woman aged 28 years with a congenital predisposition to growth of multiple adenomas of the large bowel.

In 1895, Hauser [19] noted gastroduodenal polyps in a 33-year-old patient with multiple colorectal polyps, and histological examination showed no difference from

the colorectal polyps. A severe prognosis due to malignant degeneration of the adenomas was stated in 1896 by Port [20], and in 1903 Zahlmann [21] found that only a local bowel resection was possible. In the first review of the literature in 1907, Doering [22] found 44 references to FAP. Among the patients reported, 31/37 had died from cancer. The first report of osteomas was made in 1912 by Devic & Bussy [23], and in 1916, Lillenthal [24] performed the first colectomy with ileosigmoidostomy in a 20-year-old patient who had an uneventful recovery.

Polyposis registry and prophylactic surgery

In 1925, Lockhart-Mummery stated that adenomas should be distinguished from inflammatory polyps, and that the hereditary factor in FAP is not cancer, but multiple adenomas having a marked tendency to undergo malignant change. On the basis of his early polyposis series the polyposis registry was established at St. Mark's Hospital (Figure 2) as the first in the world [25]. The first 3-stage proctocolectomy was performed in 1924 by Coffey [26].

In 1927, Cockayne [27] stated that FAP is inherited as a dominant condition, and Jüngling [28] recommended prophylactic sigmoidoscopy in the offspring of affected family members. In an extensive review, Dukes (Figure 3) named the condition “polyposis” and stated that pedigrees in a FAP family “are photographs: they record the state of affairs at a given point of time” [29]. In Leipzig, Nissen [30] published the first proctocolectomy with a straight ileoanal anastomosis, which was carried out in 1933 as a 3-stage procedure and (surprisingly) left the 10-year-old patient with normal solid stools. The first report of a periampullary cancer came from the Massachusetts General Hospital in 1935 [31].

In 1939, Lockhart-Mummery & Dukes published results from the St. Mark's Hospital Polyposis Registry, which included 10 families and the common use of prophylactic sigmoidoscopy. Five patients had a colectomy (Figure 4), and four had survived [32]. Fitzgerald published the first odontomas in 1943 [33], and in 1947, Ravitch & Sabiston [34] presented a rectal resection (pull-through procedure) and ileo-anal anastomosis carried out after a previous colectomy and ileorectal anastomosis. Lloyd-Davies carried out the first colectomy and ileorectal anastomosis at St. Mark's Hospital in 1948 [35]. In 1950, Halsted et al. [36] described the first patient with gastric polyposis diagnosed by gastroscopy, and according to the description this may represent the first case of fundic gland polyposis, but no histology was reported.

Extracolonic manifestations – Gardner's syndrome

In 1951, Gardner [37] (Figure 5) described what was later termed “Gardner's syndrome” including colorectal adenomas, desmoid tumours, bone tumours, and soft

X. POLYADENOMA TRACTUS INTESTINALIS.

Проф. Н. В. Скляфосовскаго.

Различные патологические процессы в нижней части кишечника сопровождаются функциональными расстройствами, в число которых самый постоянный — ощущение жжения и колики. При почечуиномъ (геморройномъ) перерожденіи слизистой оболочки прямой кишки это явление представляется обычнымъ; оно ожесточается въ тѣхъ случаяхъ, когда слизистая оболочка поражается катарромъ. А такъ какъ у страдающихъ почечуемъ это повторяется нерѣдко, то подобное принадлежное явление и принимается за выражение катаррального состоянія кишекъ вообще; въ дѣйствительности же оно поддерживается мѣстнымъ патологическимъ процессомъ — почечуиномъ перерожденіемъ слизистой оболочки прямой кишки. Почечуиное перерождение слизистой оболочки развивается въ самой нижней части прямой кишки, и рѣдко можно наблюдать расширеніе венъ выше, чѣмъ сантиметра на три надъ жомомъ (sphincter ani). Но воспалительные процессы и новообразования могутъ распространяться выше по кишеч-

Figure 1. The first article on FAP by Sklifasowski [9].



Figure 2. The old St. Mark's Hospital at City Road.

cyst-like surface tumours. Dukes was the first to describe the psychological aspects of the disease in 1952 and stated that “in the study of polyposis scientific enthusiasm must always be tempered with sympathy and tact” [38] Furthermore, in this article Dukes presented his poetic visions about future gene therapy:

You are old, Father William, the young surgeon said,
 And your colon from polyps is free.
 Yet most of your sibling are known to be dead –
 A really *bad* family tree.
 In my youth, Father William replied with a grin,
 I was told that a gene had mutated,
 That all who carried this dominant gene
 To polyps and cancer were *fated*.
 I sought for advice from a surgical friend,
 Who sighed and said – Without doubt
 Your only escape from an untimely end



Figure 3. Cuthbert Dukes.

Is to have your intestine right *out*.
 It seemed rather back luck – I was then but nineteen
 –
 So I went and consulted a quack,
 Who took a firm grip on my dominant gene
 And promptly *mutated it back*.
 This, said the surgeon, is something quite new
 And before we ascribe any merit
 We must see if the claims of this fellow are true,
 And observe what your *children* inherit!

The same year Dukes [39] presented detailed results based on 156 cases from 41 families in the St. Mark's Hospital Polyposis Registry. In 1955, Reed & Neel [40] presented a detailed genetic study and calculated the frequency at birth to be 1:8,300.



Figure 4. Old colectomy specimen from St. Mark's Hospital.




Figure 5. Eldon Gardner.

Lockhart-Mummery et al. reviewed the surgical treatment in 1956 on the basis of the St. Mark's series. Proctocolectomy with a straight ileoanal anastomosis was considered technically difficult with a high risk of complications and unsatisfactory functional results, whereas colectomy with an ileorectal anastomosis resulted in a "probably small" risk of rectal cancer, provided there was adequate supervision every 3–4 months. The operation should be carried out in the teens and the anastomosis should be made 10–12 cm above the anal verge [41]. Hubbard [42] noted spontaneous regression of rectal adenomas after colectomy and IRA in 1957. In 1958, Dukes stated that if by the age of 40 there are no symptoms and sigmoidoscopy is negative, it is very unlikely that polyps will develop later. The article described in detail the early years of education and psychology [43]. On the basis of a pedigree study, Veale in 1960 stated the necessity of examining all accessible relatives in a polyposis family [44]. Morson [45] presented a new histopathological classification of colorectal polyps in 1962, and, in the same year, dental abnormalities were diagnosed by Fader et al. [46]. Drobni [47] published a one-stage proctocolectomy with a pull-through anal ileostomy in 1964, and Camiel et al. [48] presented the association with thyroid carcinoma in 1968.

Nationwide registration and a new surgical option

In 1975, Bussey [49] (Figure 6) published his comprehensive thesis on the basis of the St. Mark's series, which was based on his meticulous recording of the families (Figure 7) and became a milestone in the FAP literature. Utsunomiya & Nakamura [50] reported the finding of multiple subclinical mandibular osteomas detected by pantomography. In the same year Alm in his thesis presented the results of the national registration in Sweden and calculated an incidence rate of 1:7,646 [51]. In 1977, Yao et al. [52] published the first series of patients with endoscopically diagnosed duodenal adenomas, and Watanabe et al. [53] described fundic gland

polyposis in 1978. In 1979, Hamilton et al. [54] published the first report of ileal adenomas after colectomy.

In 1980, Parks et al. [55] and Utsunomiya et al. [56] simultaneously presented a new surgical procedure: restorative proctocolectomy with mucosectomy and ileo-pouch-anal anastomosis. Blair & Trempe [57] described congenital hypertrophy of the retinal pigment epithelium (CHRPE) in 1980. Baron & Lee [58] introduced CT scan for the evaluation of mesenteric desmoid tumours in 1981, and the combination of an NSAID (clinoril) and tamoxifen was presented by Waddell et al. [59] as a treatment for a desmoid tumour. Kingston et al. [60] described the association with hepatoblastoma in 1983, and Järvinen et al. [61] described biliary adenomas in 1983. Krush et al. [62] offered the first psychosocial guide to FAP, and Miller et al. [63] described barriers to coping and adaptation. Bülow [64] published the first calculations of national survival rates in 1986.

The APC gene

In 1986, Herrera et al. [65] presented the possible association to a deletion in chromosome 5q, and in 1987, Bodmer et al. and Leppert et al. [66, 67] independently presented the location of the *APC* gene at chromosome 5q21–22. The Leeds Castle Polyposis Group (LCPG) was established in 1985 as an international research forum [68], and a multicenter LCPG study described the prevalence of upper gastrointestinal malignancy [69]. Tops et al. [70] presented presymptomatic diagnosis on the basis of DNA markers in 1989, and Spigelman et al. [71] published a new staging of duodenal adenomatosis, which was later named the Spigelman Classification. In 1990, Neal & Berrey [72] introduced MRI scanning for the evaluation of growth of a desmoid tumour, and textbooks were published by Herrera [73] and by Utsunomiya [74]. In 1991, Groden et al., Kinzler et al. and Joslyn et al. [75–77] characterised the *APC* gene in detail. Screening guidelines for molecular genetic diagnosis were published in 1991 by Petersen et al. [78], and Bradburn et al. [79] introduced the detection of microadenomas in the diagnosis of FAP. Tsukuda reported the use of systemic cytotoxic chemotherapy for desmoids [80]. In 1992, a murine FAP model (min mouse) was introduced by Su et al. [81], and Nugent & Phillips [82] stated that the risk of rectal cancer after ileorectal anastomosis was sharply rising after age 50. Levitt et al. [83] explored coping styles and highlighted problems such as cancerophobia. Spirio et al. [84] found that an attenuated form of FAP was linked to the *APC* locus, and in 1993 Nugent et al. [85] described the development of adenomas in the ileoanal pouch. A European Union research group (EuroFAP) published guidelines for the establishment of polyposis registers [86].



Figure 6. H. J. R. Bussey in the Polyposis Registry.

The latest decade

Olschwang et al. [87] published the first reported evidence of a genotype-phenotype correlation in 1994, and Giardiello et al. [88] presented sulindac as treatment for colorectal adenomatosis. Bertoni diagnosed jejunal polyps by push-enteroscopy [89]. In 1994, Lynch et al. [90] described the effect of doxorubicin and dacarbazine on unresectable desmoids, and Hoehner & Metcalf [91] described a carcinoma of the ileoanal anastomosis after restorative proctocolectomy. Also the use of the protein truncation test as a rapid method for the detection of an APC gene mutation was presented by van der Luijt et al. [92]. In the same year Phillips, Spigelman and Thomson from St. Mark's Hospital published the most recent textbook on all major aspects of FAP [93]. In 1995 the APC protein product was identified by Rubinfeld et al. [94], and Chung et al. [95] described the pancreas-sparing duodenectomy as a cancer prophylactic procedure for severe duodenal adenomatosis. Lynch et al. [96] published the first report of an attenuated

subgroup of the disease, which is now known as attenuated familial adenomatous polyposis (AFAP). Vasen et al. [97] presented molecular genetic testing as a possible guide to surgical decision making (ileorectal anastomosis versus ileoanal pouch) in 1996, and in the same year Healy et al. [98] published the first report of MRI scan for evaluation of the growth of a desmoid tumour.

In 1997, Milsom et al. [99] reported a laparoscopic colectomy with ileorectal anastomosis, and in 1998, Clark et al. [100] described the identification and progression of a desmoid precursor lesion. Steinbach et al. [101] described the effect of celecoxib on colorectal and duodenal adenomatosis in 2000. In 2002, Groves et al. [102] presented an evaluation of the risk of duodenal carcinoma, and Costamagna et al. [103] reported the diagnosis of ileal polyps detected by video capsule endoscopy. In 2003, Olsen et al. [104] demonstrated a reduced fertility after restorative proctocolectomy; Sieber et al. [105] and Sampson et al. [106] independently demonstrated that mutations in the MYH gene predispose to a recessive phenotype with multiple colorectal adenomas similar to AFAP, and Middleton et al. [107] demonstrated a stepwise progression of desmoid precursor lesions by a CT-scoring system. In the same year Burn et al. [108] presented the effect of resistant starch and aspirin on colorectal adenomas (CAPP 1 Study), and the Leeds Castle Polyposis Group and the International Collaborative Group for HNPCC merged into the International Society of Hereditary Gastrointestinal Tumours (InSiGHT) [109]. In 2004 Crabtree et al. [110] demonstrated the evidence of modifier loci for the severity of colonic adenomatosis, and Bülow et al. [111] presented a prospective evaluation of the natural course of duodenal adenomatosis.

It is impossible to document here all the publications on FAP over the years. To those we have omitted we

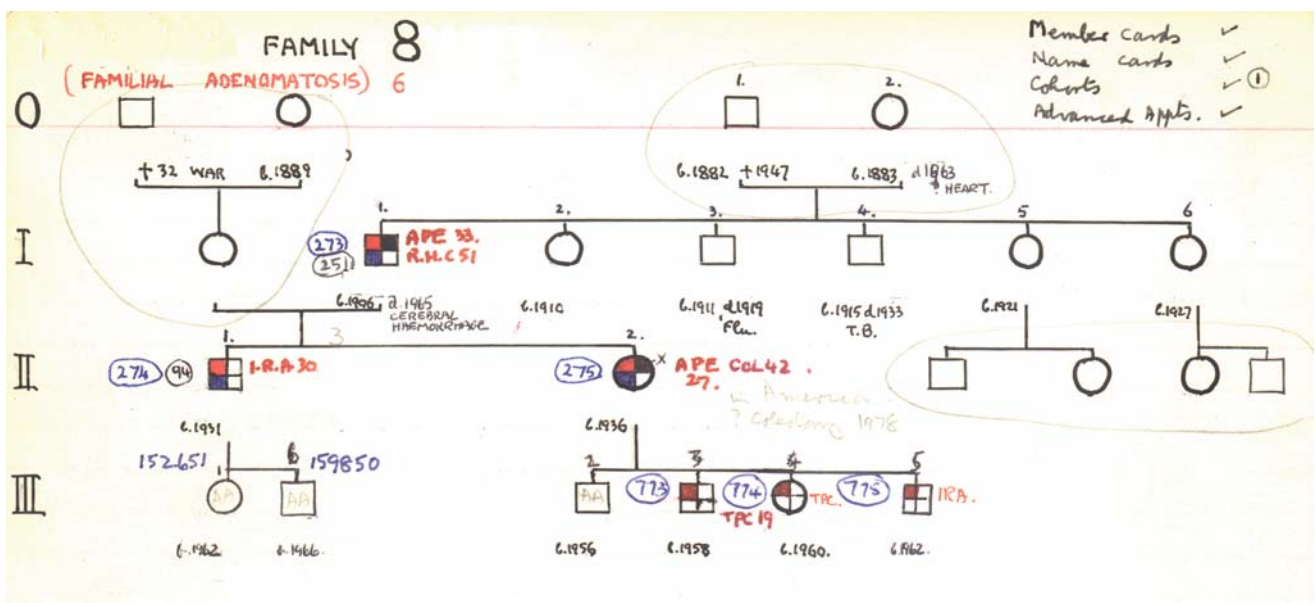


Figure 7. One of Dr. Bussey polyposis pedigrees.

offer our apologies. We have tried to represent all major advances in knowledge and understanding of the condition. It is, however, interesting to note that the truth contained in Dukes' statement of 1958 has not been altered, "It would be difficult to find a more promising field for the exercise of cancer control than a polyposis family, because both diagnosis and treatment are possible in the precancerous stage and because the results of surgical treatment are excellent" [43].

References

1. Menzel D. De excrementis verrucosus cristas copiose in intestinis crassis dysenteriam passi observatis. *Acta Med Berol* 1721; 68–71.
2. Wagner J. Einige Formen von Darmgeschwüren: Die dysenterische Darmverschwürung. *Med Jahrb des k k öst Staates* 1832; 11: 274.
3. Rokitskany C. Der dysenterische Prozess aut dem Dickdarm. *Med Jahrb des k k öst Staates* 1839; 29: 88.
4. Corvisart L. Hypertrophie partielle de la muqueuse intestinale. *Bull Soc Anat* 1847; 22: 400.
5. Lebert H. Polypes multiples sur toute la surface du colon, epaississement de tunique; pneumonie disséquante du lobe moyen droit. Diarrhée incoercible, pneumonie gangréneuse. Mort. CCCLXXII. *Traité d'anatomie pathologique générale et spéciale*. Paris: J-B Baillere et fils, 1857; 346–7.
6. Chargelaigue A. Des polypes du rectum. Thesis, Paris, 1859.
7. Luschka H. Ueber polypöse Vegetationen der gesammten Dickdarmschleimhaut. In Virchow R (ed): *Archiv für pathologische Anatomie und Physiologie und für klinische Medicin*. Berlin: Georg Reimer, 1861: 133–42.
8. Virchow R. Eilfte Vorlesung: Follicularcysten. In *Die krankhafte Geschwülste*, Berlin, Verlag von August Hirschwald, 1863.
9. Sklifasowski NW. Polyadenoma tractus intestinalis. *Vrac* 1881; 4: 55–7.
10. Woodward JJ. Pseudo-polypi of the colon. An anomalous result of follicular ulceration. *Am J Med Sci* 1881; 81: 142–55.
11. Cripps WH. Two cases of disseminated polypus of the rectum. *Transact Path Soc London* 1882; 33: 165–8.
12. Whitehead W. Multiple adenoma of colon and rectum. *Br Med J* 1884; 1: 410.
13. Smith T. Three cases of multiple polypi of the lower bowel occurring in one family. *St. Bartholomew's Hospital Reports* 1887; 23: 225–9.
14. Bickersteth RA. Multiple polypi of the rectum occurring in a mother and child. *St. Bartholomew's Hospital Reports* 1890; 26: 299–301.
15. St. Mark's Hospital, London: A social history of a specialist hospital. London: King's Fund Publishing Office, 1985, p. 268.
16. Cripps H. Polyposis of the rectum. In: *On diseases of the rectum and anus*. London, J&A Churchill, 1890, 28–298.
17. Handford H. Disseminated polypi of the large intestine becoming malignant; strictures (malignant adenoma) of the rectum and of the splenic flexure of the colon; secondary growths in the liver. *Transact Path Soc London* 1890; 61: 133–7.
18. Dalton N. Multiple papillomata of the colon and rectum. *Lancet* 1893; 1: 146.
19. Hauser G. Ueber Polyposis intestinalis adenomatosa und deren Beziehungen zur Krebsentwicklung. *Deutsche Arch Klin Med* 1895; 55: 429–48.
20. Port K. Multiple Polypenbildung im Tractus intestinalis. *Deutsche Zeitschr Chir* 1896; 42: 181–97.
21. Zahlmann S. Polypois intestini crassi. *Hospitalstidende* 1903; 51: 1267–74.
22. Doering H. Die Polyposis intestini und ihre Beziehung zur carcinomatösen Degeneration. *Arch Klin Chir* 1907; 83: 194–227.
23. Devic , Bussy . Un cas de polypose adénomateuse généralisée a tout l'intestin. *Arch Mal l'App Dig* 1912; 20: 278–89.
24. Lillienthal H. *Am Med* 1901, April 27: 164 (quoted by: Soper HW. Polyposis of the colon. *Am J M Sc* 1916; 151: 405–9).
25. Lockhart-Mummery JP. Cancer and heredity. *Lancet* 1925; 1: 427–9.
26. Coffey RC. Colonic polyposis with engrafted malignancy. *Ann Surg* 1926; 83: 364–80.
27. Cockayne EA. Heredity in relation to cancer. *Cancer Rev* 1927; 2: 337–47.
28. Jüngling O. Polyposis Intestini. Hereditäre Verhältnisse und Beziehungen zum Carcinom. *Beitr Klin Chir* 1928; 143: 476–83.
29. Dukes C. The hereditary factor in polyposis Intestini, or multiple adenomata. *Cancer Rev* 1930; 5: 241–56.
30. Nissen R. (Case story). *Zentralblatt Chir* 1933; 15: 888.
31. Cabot RC. Case records of the Massachusetts General Hospital Case 21061. *N Engl J Med* 1935; 212: 263–7.
32. Lockhart-Mummery JP, Dukes CE. Familial adenomatosis of colon and rectum. Its relationship to cancer. *Lancet* 1939; 2: 586–9.
33. Fitzgerald GM. Multiple composite odontomes coincidental with other tumorous conditions: Report of a Case. *J Am Dental Assoc* 1943; 30: 1408–17.
34. Ravitch MM, Sabiston DC. Anal ileostomy with preservation of the sphincter. *SGO* 1947; 84: 1095–99.
35. Thomson JPS. Familial adenomatous polyposis: the large bowel. *Ann Roy Coll Surg Engl* 1990; 72: 177–80.
36. Halsted JA, Harris EJ, Bartlett MK. Involvement of the stomach in familial polyposis of the gastro-intestinal tract. *Gastroenterology* 1950; 15: 763–70.
37. Gardner EJ. A genetic and clinical study of intestinal polyposis, a predisposing factor for carcinoma of the colon and rectum. *Am J Hum Gen* 1951; 3: 167–76.
38. Dukes CE. Familial intestinal polyposis. *Ann Roy Coll Surg Eng* 1952; 10: 293–304.
39. Dukes CE. Familial intestinal polyposis. *Ann Eugen* 1952; 17: 1–29.
40. Reed E, Neel JV. A genetic study of multiple polyposis of the colon (with an appendix deriving a method of estimating relative fitness). *Am J Hum Gen* 1955; 7: 236–63.
41. Lockhart-Mummery HE, Dukes CE, Bussey HJR. The surgical treatment of familial polyposis of the colon. *Br Jr Surg* 1956; 43: 476–81.
42. Hubbard TB. Familial polyposis of the colon: the fate of the retained rectum after colectomy in children. *Am Surg* 1957; 23: 577–86.
43. Dukes CE. Cancer control in familial polyposis of the colon. *Dis Col Rect* 1958; 1: 413–23.
44. Veale AMO. Clinical and genetic problems in familial intestinal polyposis. *Gut* 1960; 1: 285–90.
45. Morson BC. Precancerous lesions of the colon and rectum. *JAMA* 1962; 179: 104–9.
46. Fader M, Kline SN, Spatz SS, Zubrow HJ. Gardner's syndrome (intestinal polyposis, osteomas, sebaceous cysts) and a new dental discovery. *Oral Surg* 1962; 15: 152–72.
47. Drobni A. One-stage proctocolectomy with anal ileostomy. *Dis Colon Rectum* 1964; 7: 116–7.
48. Camiel MR, Mule JE, Alexander LI. Association of thyroid carcinoma with Gardner's syndrome in siblings. *N Engl J Med* 1968; 9: 1056–8.
49. Bussey HJR. Familial polyposis coli. Family studies, histopathology, differential diagnosis and results of treatment. Baltimore: Johns Hopkins University Press, 1975.
50. Utsunomiya J, Nakamura T. The occult osteomatous changes in the mandible in patients with familial polyposis coli. *Br J Surg* 1975; 62: 45–51.
51. Alm T. Surgical treatment of hereditary adenomatosis of the colon and rectum in Sweden during the last 20 years. Part I and II. *Acta Chir Scand* 1975; 141: 218–27 and 228–7.

52. Yao T, Iida M, Ohsato K et al. Duodenal lesions in familial polyposis of the colon. *Gastroenterology* 1977; 73: 1086–92.
53. Watanabe H, Enjoji M, Yao T, Ohsato K. Gastric lesions in familial adenomatosis coli. *Hum Pathol* 1978; 9: 269–83.
54. Hamilton SR, Bussey HJR, Mendelsohn G et al. Ileal adenomas after colectomy in nine patients with adenomatous polyposis coli/Gardner's syndrome. *Gastroenterology* 1979; 77: 1252–7.
55. Parks AG, Nicholls RJ, Belliveau P. Proctocolectomy with ileal reservoir and anal anastomosis. *Br J Surg* 1980; 67: 533–8.
56. Utsunomiya J, Iwama T, Imajo M et al. Total colectomy, mucosal proctectomy, and ileoanal anastomosis. *Dis Colon Rectum* 1980; 23: 459–66.
57. Blair NP, Trempe CL. Hypertrophy of the retinal pigment epithelium associated with Gardner's syndrome. *Am J Ophthalmol* 1980; 90: 661–7.
58. Baron RL, Lee JKT. Mesenteric desmoid tumours: sonographic and computer-tomography. *Radiology* 1981; 140: 777–9.
59. Waddell WR, Gerner RE, Reich MP. Nonsteroidal antiinflammatory drugs and tamoxifen for desmoid tumors and carcinoma of the stomach. *J Surg Oncol* 1983; 22: 197–211.
60. Kingston JE, Herbert A, Draper GJ et al. Association between hepatoblastoma and polyposis coli. *Arch Dis Child* 1983; 58: 959–62.
61. Järvinen HJ, Nyberg M, Peltokallio P. Biliary involvement in familial adenomatous polyposis. *Dis Colon Rectum* 1983; 26: 525–8.
62. Krush AJ, Evans KA. In Carter CO: Family studies in genetic disorders. Springfield, IL, Charles C Thomas, 1984.
63. Miller HH, Bauman LJ, Friedman DR et al. Psychosocial adjustment of familial polyposis patients and participation in a chemoprevention trial. *Int J Psychiatry Med* 1986; 16: 211–30.
64. Bülow S. Clinical features in familial polyposis coli. Results of the Danish Polyposis Register. *Dis Colon Rectum* 1986; 29: 102–7.
65. Herrera L, Kakati S, Gibas L et al. Gardner syndrome in a man with an interstitial deletion of 5q. *Am J Med Genet* 1986; 25: 473–6.
66. Bodmer WF, Bailey CJ, Bodmer J et al. Localization of the gene for familial adenomatous polyposis on chromosome 5. *Nature* 1987; 328: 614–6.
67. Leppert M, Dobbs M, Scambler P. The gene for familial polyposis maps to the long arm of chromosome 5. *Science* 1987; 238: 1411–3.
68. Northover JM. Activities of the Leeds Castle Polyposis Group. *Semin Surg Oncol* 1987; 3: 118–9.
69. Jagelman DG, DeCosse JJ, Bussey et al. Upper gastrointestinal cancer in familial adenomatous polyposis. *Lancet* 1988; i: 1149–51.
70. Tops CMJ, Wijnen JT, Griffioen G et al. Presymptomatic diagnosis of familial adenomatous polyposis by bridging DNA markers. *Lancet* 1989; ii: 1361–3.
71. Spigelman AG, Williams CB, Talbot IC et al. Upper gastrointestinal cancer in patients with familial adenomatous polyposis. *Lancet* 1989; 2: 783–5.
72. Neal J, Berrey BH. Magnetic resonance appearance of fibromatosis. A report of 14 cases and review of the literature. *Skeletal Radiol* 1990; 19: 495–9.
73. Herrera L (Eds). *Familial Adenomatous Polyposis*. New York: Alan R Liss, 1990.
74. Utsunomiya J and Lynch HT (Eds). *Hereditary Colorectal Cancer*. Tokyo: Springer-Verlag, 1990.
75. Groden J, Thliveris A, Samowitz W et al. Identification and characterization of the familial adenomatous polyposis gene. *Cell* 1991; 66: 589–600.
76. Kinzler KW, Nilbert MC, Su L-K et al. Identification of FAP locus genes from chromosome 5q21. *Science* 1991; 253: 661–5.
77. Joslyn G, Carlson M, Thliveris A et al. Identification of deletion mutations and three new genes at the familial polyposis locus. *Cell* 1991; 66: 601–13.
78. Petersen GM, Slack J, Murday V. Screening guidelines and premorbid diagnosis of familial adenomatous polyposis. *Gastroenterology* 1991; 100: 1658–64.
79. Bradburn DM, Gunn A, Hastings A et al. Histological detection of microadenomas in the diagnosis of familial adenomatous polyposis. *Br J Surg* 1991; 78: 1394–5.
80. Tsukuda K, Church JM, Jagelman DG et al. Systemic cytotoxic chemotherapy and radiation therapy for desmoid in familial adenomatous polyposis. *Dis Colon Rectum* 1991; 34: 1090–2.
81. Su L-K, Kinzler KW, Vogelstein B et al. Multiple intestinal neoplasia caused by a mutation in the murine homolog of the APC gene. *Science* 1992; 256: 668–70.
82. Nugent KP, Phillips RKS. Rectal cancer risk in older patients with familial adenomatous polyposis and an ileorectal anastomosis: a cause for concern. *Br J Surg* 1992; 79: 1204–6.
83. Levitt AJ, Rodin G, Cohen Z et al. Coping styles, psychopathology and intellectual performance in patients with familial adenomatous polyposis. *General Hospital Psychiatry* 1992; 14: 61–68.
84. Spirio L, Otterud B, Stauffer D et al. Linkage of a variant or attenuated form of adenomatous polyposis coli to the adenomatous polyposis (APC) gene. *Am J Hum Genet* 1992; 51: 92–100.
85. Nugent KP, Spigelman AD, Nicholls RJ et al. Pouch adenomas in patients with familial adenomatous polyposis. *Br J Surg* 1993; 80: 1620.
86. Bülow S, Burn J, Neale K et al. The establishment of a polyposis register. *Int J Colorectal Dis* 1993; 8: 334–8.
87. Olschwang S, Turet A, Laurent-Puig P et al. Restriction of ocular fundus lesions to a specific subgroup of APC mutations in adenomatous polyposis coli patients. *Cell* 1993; 75: 959–68.
88. Giardiello FM, Hamilton SR, Krush AJ et al. Treatment of colonic and rectal adenomas with sulindac in familial adenomatous polyposis. *N Engl J Med* 1993; 328: 1313–6.
89. Bertoni G, Sassatelli R, Tansini P et al. Jejunal polyps in familial adenomatous polyposis assessed by push-type endoscopy. *J Clin Gastroenterol* 1993; 17: 343–7.
90. Lynch HT, Fitzgibbons R Jr, Chong S et al. Use of doxorubicin and dacarbazine for the management of unresectable intra-abdominal desmoid tumors in Gardner's syndrome. *Dis Colon Rectum* 1994; 37: 260–7.
91. Hoehner JC, Metcalf AM. Development of invasive adenocarcinoma following colectomy with ileoanal anastomosis for familial polyposis coli. *Dis Colon Rectum* 1994; 37: 824–8.
92. Van der Luijt R, Khan PM, Vasen H et al. Rapid detection of translation-terminating mutations at the adenomatous polyposis coli (APC) gene by direct protein truncation test. *Genomics* 1994; 20: 1–4.
93. Phillips RKS, Spigelman AD and Thomson JPS (Eds). *Familial Adenomatous Polyposis and Other Polyposis Syndromes*. London: Edward Arnold, 1994.
94. Rubinfeld B, Souza B, Albert I et al. The APC protein and E-cadherin form similar but independent complexes with β -catenin and plakoglobin. *J Biol Chem* 1995; 270: 5549–55.
95. Chung RS, Church JM, van Stolk R. Pancreas-sparing duodenectomy: Indications, surgical technique, and results. *Surgery* 1995; 117: 254–9.
96. Lynch HT, Smyrk T, McGinn T et al. Attenuated familial adenomatous polyposis (AFAP). A phenotypically and genetically distinctive variant of FAP. *Cancer* 1995; 76: 2427–33.
97. Vasen HF, van der Luijt RB, Slors JF et al. Molecular genetic tests as a guide to surgical management of familial adenomatous polyposis. *Lancet* 1996; 348: 433–5.
98. Healy JC, Reznick RH, Clark SK et al. MR appearances of desmoid tumours in familial adenomatous polyposis. *AJR* 1996; 169: 465–72.
99. Milsom JW, Ludwig KA, Church JM, Garcia-Ruiz A. Laparoscopic total abdominal colectomy with ileorectal anastomosis for familial adenomatous polyposis. *Dis Colon Rectum* 1997; 40: 675–8.
100. Clark SK, Johnson Smith TGP, Katz DE et al. Identification and progression of a desmoid precursor lesion in patients with familial adenomatous polyposis. *Br J Surg* 1998; 85: 970–3.

101. Steinbach G, Lynch P, Phillips RK, Wallace MH et al. The effect of celecoxib, a cyclooxygenase-2 inhibitor, in familial adenomatous polyposis. *N Engl J Med* 2000; 342: 1946–52.
102. Groves C, Saunders BP, Spigelman AD et al. Duodenal cancer in patients with familial adenomatous polyposis (FAP): results of a 10 year prospective study. *Gut* 2002; 50: 636–41.
103. Costamagna G, Shah SK, Riccioni ME et al. A prospective trial comparing small bowel radiographs and video capsule endoscopy for suspected small bowel disease. *Gastroenterology* 2002; 123: 999–1005.
104. Olsen KØ, Juul S, Bülow S et al. Female fecundity before and after operation for familial adenomatous polyposis. *Br J Surg* 2003; 90: 227–31.
105. Sieber OM, Lipton L, Crabtree M et al. Multiple colorectal adenomas classic adenomatous polyposis and germ-line mutations in MYH. *N Engl J Med* 2003; 348: 791–9.
106. Sampson JR, Dolwani S, Jones S et al. Autosomal recessive colorectal adenomatous polyposis due to inherited mutations of MYH. *Lancet* 2003; 362: 39–41.
107. Middleton SB, Clarks SK, Matravers P et al. Stepwise progression of familial adenomatous polyposis-associated desmoid precursor lesions demonstrated by a novel CT scoring system. *Dis Colon Rectum* 2003; 46: 481–5.
108. Burn J, Chapman PD, Bishopp DT et al. Results of the CAPP1 Study: Aspirin and resistant starch are beneficial in familial adenomatous polyposis. *Familial Cancer* 2003; 2(Suppl. 1): 43.
109. Neale K, Bülow S. on behalf of the Leeds Castle Polyposis Group. *Familial Cancer* 2003; 2(Suppl. 1): 1–2.
110. Crabtree MD, Fletcher C, Churchman M et al. Analysis of candidate modifier loci for the severity of colonic familial adenomatous polyposis, with evidence for the importance of the N-acetyl transferases. *Gut* 2004; 53: 271–6.
111. Bülow S, Björk J, Christensen IJ et al. Duodenal adenomatosis in familial adenomatous polyposis. *Gut* 2004; 53: 381–6.